

Mid Term Results of Total Hip Arthroplasty for Various Hip Disorders

Sanjeev Gupta, Rashid Anjum, Omeshwar Singh, Anil Gupta, Abdul Ghani,
Mohammad Azhar ud din Darokhan

Abstract

The current study was undertaken to evaluate the clinical and functional outcomes of Total Hip Replacement using Modified Harris Hip score and radiological assessment. This prospective study was carried out on 47 hips of 44 patients needing Total Hip Replacement over a period of one year. Patients were followed for a minimum of 6 months to a maximum of 18 months. Excellent or good pain relief and function were obtained in 85.7% of patients after THR, which was performed in a population of active patients. The mean total pre operative score was 42.13, which improved post operatively to a mean score of 94.4. In this series 90.9 % of patients showed excellent results and no patient had poor results. Our study suggests that the current generation implants can provide satisfactory clinical and radiographic outcomes after an intermediate duration of follow-up. Though the study was not free of complications, the overall functional and clinical outcome showed good results.

Key Words

Total Hip Replacement, Modified Harris Hip Score, Osteoarthritis

Introduction

Total hip arthroplasty (THA) has become the gold standard treatment for patients with end stage arthritis (1). Multiple studies have demonstrated that THA improved the physical function and quality of life significantly (2-4). Indications for THA have increased in the last decades, along with the number of procedures performed annually (5). Almost 1 million of THA was implanted worldwide annually, with a predicting increase of 174% to nearly 600,000 THA procedures annually by 20305, (6).

Material and Methods

This prospective study was conducted in department of orthopedics Govt. Medical College Jammu. A total of 47 hips in 44 patients undergoing total hip arthroplasty between June 2012 to August 2014 were included in the

study. There were 31 males and 13 female patients. In three male patients, bilateral total hip arthroplasty was done in two sittings at 3 weeks interval. The mean age of patients was 48.85 years (range 28 to 68 years). Most common etiology was avascular necrosis of the femoral head in 21 patients. The patients were followed for a minimum of 6 months and maximum of 18 months. All the patients were available for follow up.

In our series, we used modified Hardinge approach, wherein a lazy j incision was made over the greater trochanter patient being in lateral position. Hip joint was approached by splitting the anterior one third of gluteus medius and vastus muscles; tensor fascia lata was split in line with femur and the capsule was incised sharply by keeping it under tension by flexing the knee and rotating

From the Department of Orthopedics, Government Medical College, Jammu-J&K India

Correspondence to : Dr Sanjeev Gupta, Asst. Professor, Department of Orthopedics, Government Medical College, Jammu-J&K

it externally. In two cases we came across excessive bleeding due to a previous surgical procedure performed in the same hip. Haemostasis was achieved with ligatures and cautery. The capsule was excised and the hip was dislocated by flexing and externally rotating the hip. On dislocating, the femoral head was extracted after neck osteotomy which was performed according to our pre-planned template. The acetabulum was prepared excising the soft tissues attached to it and reaming it up to the bleeding subchondral bone. All the osteophytes, if present were excised and the wound irrigated to remove any leftover debris. Morcellised femoral head as graft was used to cover the defect in the acetabulum caused by subchondral cyst in acetabulum. Acetabular cup sizes used were one size higher than the last reamer used. In all the patients we used screws to fix the acetabular cup along the posterosuperior quadrant keeping in mind centre of the offset placed superiorly or posterosuperiorly. The acetabular cup placed was covered with a mop to protect it from any debris. The proximal femur was exposed and delivered out by external rotating the limb. The femoral canal was hand reamed to the anticipated stem size as determined by templating and maintaining the anteversion. On introducing the femoral stem, the stability was tested to rotational and extraction forces and care was taken not to fracture the proximal femur. The prosthetic head of the appropriate size was placed on the trunion and affixed with mallet over a plastic capped head impactor. A wash was given and any remaining debris removed. The femoral head was reduced and stability confirmed through a functional range of motion. Wound was closed over a suction drain.

Results

The short and intermediate term results of the patients were analyzed. The minimum follow-up was 6 months and maximum being 18months, they are currently under our follow up. The mean age in our series was 48.85 years (range 28-68 years) with 31 males and 13 female patients. The mean blood loss in our patients was 350 ml

and on an average each patient was given one transfusion of whole blood. In our series left side was operated in 26 patients(55.31%) and right side in 21 patients(44.68%). The mean Pre-operative Harris hip score was 42.13 which improved to 94.4 at last follow up. We used prosthesis of depuy in 28 patients ,zimmer in 19 patients.

Fig 1 AVN Femur Head Left Side

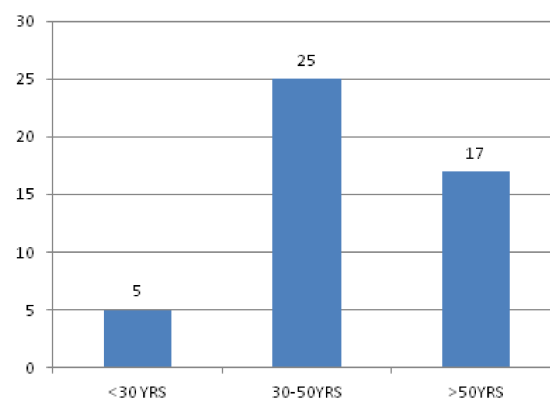


Fig 3. Indication for Surgery

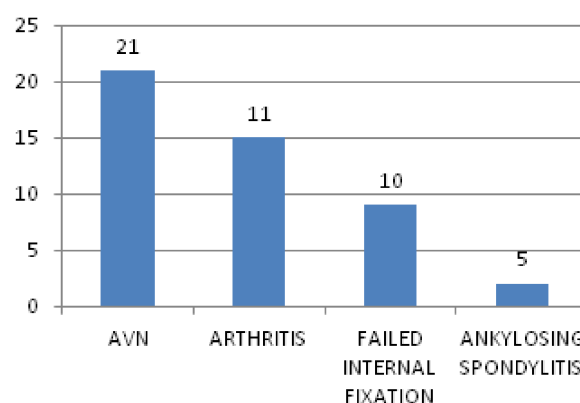


Fig 5. Femoral Head Side

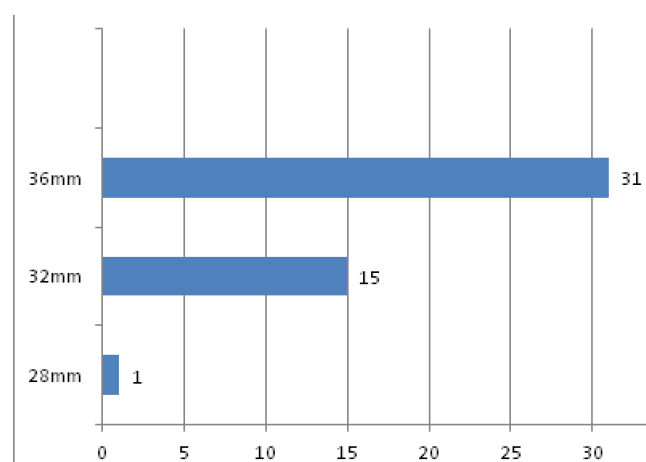
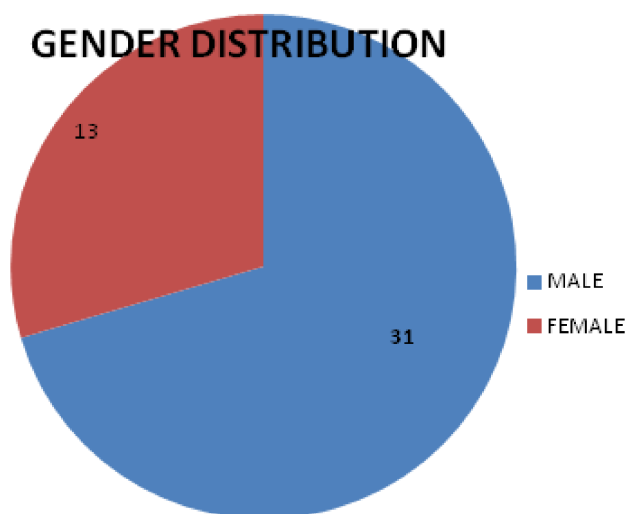


Fig 2 Gender Distribution



Head size 32 (46.80%) was most commonly used followed by 36 (44.68%).

Discussion

The age limit for this series was upto 68 years. In western literature, as per Charnley (7), Harkness (8), Eftekhari (9) total hip arthroplasty has primarily been described for patients in older age group of sixty and above. In our study 17 (38.63%) of the patients were found to be in the 50 and above age group. Majority 31 (70.45%) were males and 13 (29.54%) were females. Many series have shown that the rate of loosening and revision of total hip arthroplasty is high in younger patients. The cemented acetabular component has been the source of most of these failures. The short-term results of cementless acetabular reconstruction have been encouraging in young patients. Berger *et al* reported a 10-year survival of 98.8% in patients younger than 50 years (10).

Harris hip score is the most widely used scoring system for evaluating hip arthroplasty (11). We used Modified Harris hip score to assess the functional outcome in our study. Singling out the primary indication of the procedure is difficult, but reports of Harkness and Eftekhari document arthritis group to be the most common indication. Avascular necrosis of femoral head (45.45%) followed by arthritis due to other causes (22.72%) were the

Fig4. Side Affected (Right Vs Left)

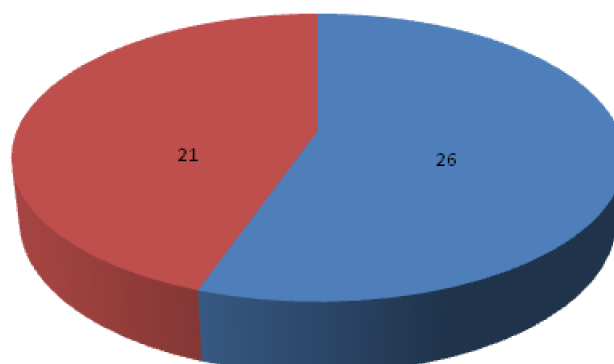
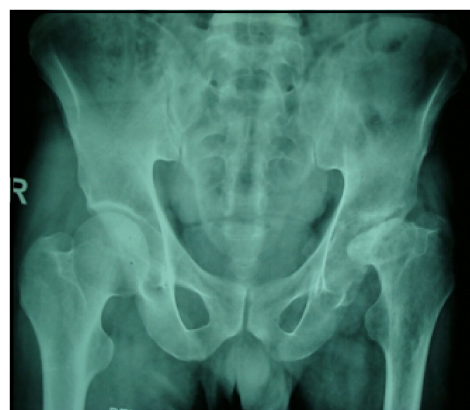

Fig 6. AVN Femur Head Left Side



indications in our study. There were 5 cases of Ankylosing Spondylitis and ten cases of failed internal fixation for fracture neck of femur. Studies in the west report Osteoarthritis as the most common diagnosis (63% by Harris *et al* & 77% by Berger *et al* (12). Avascular necrosis is the second most common diagnosis in the western literature (10% by Harris *et al* (12) & 7% by Berger *et al* (10). In this series, the difference in diagnosis might suggest a high rate of A.V.N. and a low rate of osteoarthritis in Indian patients. A study for longer period of time and with longer follow up is needed to establish this fact and to determine the reason for this difference. Antibiotic chemoprophylaxis was routinely carried out in all patients. No patient developed deep infection and only two cases of superficial infection were detected. All surgeries were performed in conventional operating theatre. Goldberg *et al* (13) reported a rate of 0.8% of

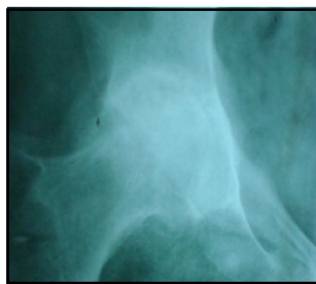


Fig 7. Ankylosing Spondylitis

deep infection using vertical laminar flow operating rooms and body exhaust systems. No case of deep infection in the present study highlights the importance of proper operating room discipline along with prophylactic antibiotics. Patients were evaluated after discharge at 4 weeks, 2 months and, at 6 months. Average follow up was from 6-18 months in this study, as compared to much larger follow ups available in western literature (42 months by Harris *et al* (12), 8.6 years by Goldberg *et al* (13) and 103 months by Berger *et al* (10). Mean Harris hip score improved from 42.13 points preoperatively to 94.4 points postoperatively. 90.9% of hip were graded as excellent in this study, 9.09% were graded good. There was no patient with poor result in our study. Harris *et al* (12) reported improvement in Harris hip score from 57 preoperatively to 93 points postoperatively. 96% good to excellent results, 4% fair and no poor results were reported. Goldberg *et al* (13) reported improvement in Harris hip score from 47 preoperatively to 88 points postoperatively. 85% good to excellent results, 13% fair and 9% poor results obtained in his series. These figures were comparable to our results. Pain relief was also dramatic following THR. 54.5% of the patients had marked pain preoperatively and 45% had moderate pain. Postoperatively 72.7% of patients got complete relief of pain and 27.27% patients had slight or occasional pain. Similar result was obtained by Harris *et al* (12) (98% complete pain relief) and Berger *et al* (10) (94.5% complete pain relief). No limp was seen in 68.18% and Slight limp was seen in 31.8% of patients in this study. In a study by Harris 63% patients had no limp and 28% of patients had slight limp. Berger *et al* (10) also reported

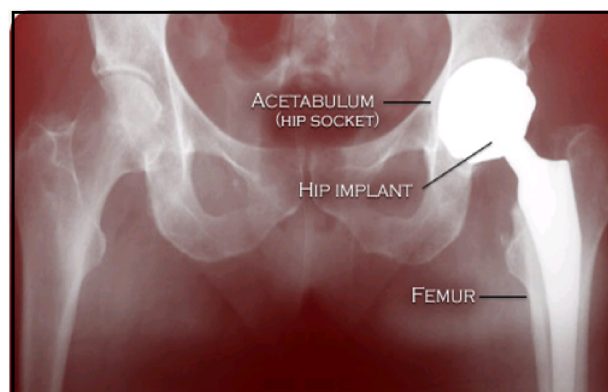


Fig 8. Postoperative Radiograph Showing Thr Done On Left Side

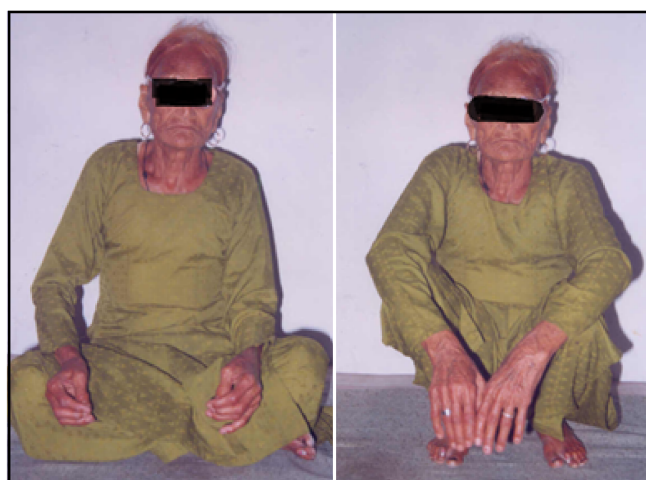

Fig.9 Operated Case of THR on Left Side at 6 Months Follow up patient able to sit cross legged (Fig 4a) and able to squat (Fig 4b)

low rate of limping. The limping improves over a period of time with progressive abductor exercises. As this study has a short follow up, percentage of patients limping are expected to decrease with time. 86.36% patients needed no support and 13.63% of patients required occasional cane for walking long distances. No patient in our study required cane full time. This finding is comparable to the results obtained by Harris *et al* (12) (95% patients used cane occasionally). Extensive pedestal formation is considered another potential radiographic sign of instability of the implant. In our series this was not seen in any of the cases. However, our follow-up may have been too short. Studies with longer follow-up have demonstrated a notably higher prevalence of femoral osteolysis.

Radiographically results were also excellent. Only one case had a cemented acetabular component and rest were uncemented. Femoral component was cemented in 17 patients and uncemented in rest of the patients. Second generation cementing techniques were used for the cases in which cementing was done. No hip showed any evidence of loosening or osteolysis in femoral and acetabular component. Goldberg *et al* (13) reported revision of one acetabular component for recurrent dislocation (0.8%) and one stem revision for mechanical loosening, one stem radiographically loose. However as our study has very short follow up, definite conclusions can only be drawn after longer follow up. Low complications were seen in our series. In two cases superficial infection were seen and one patient had a dislocation which was reduced by closed means. Harris *et al* reported 5 cases of trochanteric non-union (8%), 19 cases of deep vein thrombosis (15%), 9 dislocation (7%), 2 partial femoral and sciatic nerve paralysis and 2 patients had peroneal nerve paralysis (1.5% each). Goldberg *et al* had 3 dislocations (2.4%), 1 deep infection (0.8%) and 3 deep vein thrombosis (2.4%).

The study aims at evaluating the short and intermediate term outcome of primary total hip arthroplasty. While our study was limited to 47 total hip arthroplasties, Berger *et al* (10) performed 150 T.H.A., Harris *et al* (12) performed 126 T.H.A. and Goldberg *et al* (13) performed 125 T.H.A. It was due to the fact that this study was limited to a very short duration. Also, financial constraints and lack of awareness of this procedure to the patient limited the number of patients for this study.

Conclusion

In conclusion, the outcome of total hip arthroplasty is determined by multiple factors, including the design of the component, the selection of the patients, and the operative technique. Our study suggests that the current generation implants can provide satisfactory clinical and radiographic outcomes after an intermediate duration of follow-up. The overall functional and clinical outcome showed good results.

References

1. Schwarzkopf R, Mikhael B, Wright E, *et al*. Treatment failure among infected periprosthetic total hip arthroplasty patients. *Open Orthop J* 2014; 8: 118-24.
2. Barrett J, Losina E, Baron JA, *et al*. Survival following total hip replacement. *J Bone Joint Surg Am* 2005; 87: 1965-71.
3. Ackerman IN, Graves SE, Bennell KL, *et al*. Evaluating quality of life in hip and knee replacement: psychometric properties of the World Health Organization Quality of Life short version instrument. *Arthritis Rheum* 2006; 55: 583-90.
4. Liu SS, Della Valle AG, Besculides MC, *et al*. Trends in mortality, complications and demographics for primary hip arthroplasty in the United States. *Int Orthop* 2009; 33: 643-51.
5. Crowninshield RD, Rosenberg AG, Sporer SM. Changing demographics of patients with total joint replacement. *Clin Orthop Relat Res* 2006; 443: 266-72.
6. Kurtz S, Ong K, Lau E, *et al*. Projections of primary and revision hip and knee arthroplasty in the United States from 2005 to 2030. *J Bone Joint Surg Am* 2007; 89: 780-85.
7. Charnley J. Low Friction Arthroplasty of the Hip: Theory and Practice. Springer-Verlag, Berlin, Heidelberg, New York, 1979. pp.23-28
8. Harkess JW. Arthroplasty of hip. In: Crenshaw AH (editor), Campbell's Operative Orthopaedics, 8th edition. CV Mosby Company, St. Louis, Washington DC, Tronto, 1982: Vol. 1.pp.34-8
9. Eftekhari NS Total hip replacement using principles of low-friction arthroplasty: The Hip. In: Evarts CM (editor), Surgery of the Musculoskeletal System. Churchill Livingstone, 1983: Vol.3.pp.13-23
10. Berger R A. Primary cementless acetabular reconstruction in patients younger than 50 years old. *Clin Orthop* 1997;249:216-26.
11. Sharma S, Kingsley S, Bhamra P. Primary total hip replacement for acute displaced subcapital femoral fractures. *British Ed Society Bone Joint Surgery* 2006; 88-B(S1): 168.
12. Harris WH, Maloney WJ. Hybrid total hip arthroplasty. *Clin Orthop* 1989; 249: 21-29.
13. Goldberg VM. Hybrid total hip arthroplasty 7 to 11 year follow up. *Clin Orthop* 1996; 333: 147-54.